

## Effect of Venous Anastomotic Numbers on the Outcome of Free Tissue Transfer

AHMED M. ALY, M.D. and MAHFOUZ S. IBRAHIM, M.D.

*The Department of General Surgery, Plastic Surgery Unit, Faculty of Medicine, Zagazig University, Zagazig, Egypt*

### ABSTRACT

**Background:** The Benefit of the second venous anastomosis for free flap success is still controversial issue between micro-surgeons. While some studies have pointed to its valuable effect, others have refused this role. In this work, the effect of the number of venous anastomosis on the free flap success is studied.

**Patients and Method:** This retrospective study reviews and analyzes the results of forty seven free flaps that operated by the authors through the last eight years, flaps were assigned to group A if they have single venous anastomosis and group B if they have double anastomosis.

**Results:** The overall complication rate was 23.4%, vascular compromise occurred in 17% of cases, and failure rate was 12.7%. The incidence of venous thrombosis was 8.51% in group A and 6.38% in group B. statistical analysis of results revealed that neither second venous anastomosis nor smoking had significant effect on flap success.

**Conclusion:** Double venous anastomosis is not recommended as guarantee against venous insufficiency.

**Key Words:** Venous anastomosis – Free flap – Thrombosis.

### INTRODUCTION

A free tissue transfer occupies the forefront position in a complex defect reconstruction in the modern surgery with more than 90% success rate [1]. Nevertheless vascular compromise still occurs necessitating anastomotic revision or leads to catastrophic flap loss [2]. When vascular insufficiency developed, venous obstruction is a far more prevalent cause than arterial thrombosis [3-9]. Many efforts were spent to prevent this disastrous event through heparin infusion, improving hydration status or preforming multiple venous anastomosis, [10-12] hypothesizing that, if one vein is occluded the other one will save the flap, [2] but this assumption is still controversial between micro-surgeon

and many refusing it [13,14]. In this study all cases of free flap that operated by the authors through the previous eight years are reviewed to determine the effect of multiple venous anastomosis on the flap survival.

### PATIENTS AND METHODS

This retrospective study reviews the work in which the authors were involved (either main surgeon or assistant) during the last eight years in the plastic surgery unit of Zagazig university hospital (from January 2008 to January 2016). Forty seven free flaps were included in this study, the indications for flap transfer were soft tissue coverage after tumor resection, traumatic tissue loss, functional muscle transfer, and breast reconstruction. Other patient data were collected, including age, sex, co-morbidity (diabetes and hypertension), smoking status or drug addiction, operative site, total operative and vascular anastomosis time, blood transfusion, anastomotic revision, major and minor complications. Moreover, all smoker patients were instructed to stop smoking once the decision of flap coverage is taken until they charged from hospital. Details of flaps is shown in Table (1).

**Operative technique:** Details for flaps dissection is out of scope in this paper, but generally our attitude during flap harvesting was to preserve as much vessels as we can. The number of venous anastomosis was decided based on the condition of the available veins. For single vein flaps (latissimus dorsi) only one anastomosis was possible, yet other flaps our default choice was to do double anastomosis unless the condition of the other vessel was not suitable for anastomosis, or there is no good recipient vein. Out of forty seven flaps, in twenty three flap there were single venous anasto-

mosis (group A) and in twenty four flaps double venous anastomosis were done (group B), table two showed the details.

Postoperatively all our patients have been transferred to ICU where they have received the same regimen; full I.V hydration (3000 cc/day) and any decrease of blood pressure was managed with fluid, no vasopressors were allowed. Low molecular weight heparin (enoxaparin) was given in a dose of 1mg/kg twice a day for five days which was

replaced by aspirin in next two weeks, and patients' surrounding were kept warm and devoid of smoking. Hemodynamic of the patients was followed by urinary output ( $\geq 1\text{ml/minute}$ ) and CVP monitoring ( $\geq 5\text{mmHg}$ ), and flaps were monitored by classical features (color, capillary refilling, turgor, temperature, oozing).

Chi-square test was used to analyze the results, SPSS16 program was used.

Table (1): Demographic data.

Flaps	Total number	Mean age	Sex		Indication of flap transfer			
			M	F	Traumatic	Post resection	Functional transfer	Aesthetic
Radial forearm	13	44 $\pm$ 5.9	8	5	4	9	0	0
Gracilis	4	30.5 $\pm$ 5.1	4	0	0	0	4	0
Latissimus dorsi	9	31.3 $\pm$ 1	6	3	7	2	0	0
Rectus femoris	6	36.5 $\pm$ 9.3	5	1	4	2	0	0
Free TRAM	15	40.2 $\pm$ 4.1	0	15	0	0	0	15
Total	47	38.14 $\pm$ 8.8	23	24	15	13	4	15
%					31.9%	27.7%	8.5%	31.9%

Table (2): Venous anastomosis.

Flaps	Number of venous anastomosis	
	Single	Double
Radial forearm	3	10
Gracilis	4	0
Latissimus dorsi	9	0
Rectus femoris	2	4
Free TRAM	5	10
Total	23	24

## RESULTS

Through this study eleven patients (23.4%) were returned to OR for surgical interference, in three of them (6.3%) there were increasing hematomas in spite of presence of drains, in those patients hematomas were removed and hemostasis was revised and in all of them the flaps did well after that.

Vascular compromise was noticed in eight patients (17%) during the next three days that follow the surgery. Urgent exploration was carried,

the exploration revealed arterial thrombosis in one case from group A (2.1%), and venous thrombosis in the remaining seven cases (14.9%), they were four from group A (8.5%) and three in group B (6.38%). Thrombectomy was done and vessels were flushed with saline-heparin solution and anastomoses were revised (for the artery or one vein). Only two flaps saved (that with arterial thrombosis and one in group B with venous occlusion), one of them returned back to OR for debridement. The other six were not salvageable (failure rate was 12.7%). Most cases required vascular revision (six cases 75%) occurred in the first four years in this study. When the incidence of complications was statistically analyzed, the two groups did not revealed statistical difference regarding the incidence of venous thrombosis ( $p>0.05$ ). There was no statistical correlation between smoking history and the occurrence of vascular complication in our study group, as only two out of twelve smoker patients developed vascular trouble (16.6%), whereas in non-smoker patients the incidence of similar complication was 17.1% (six out of thirty five).



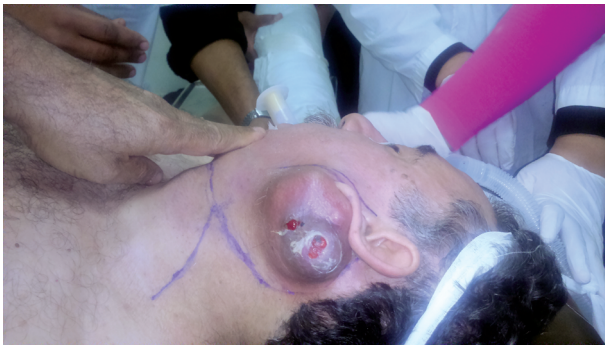

Fig. (1): Parotid tumor infiltrating skin.

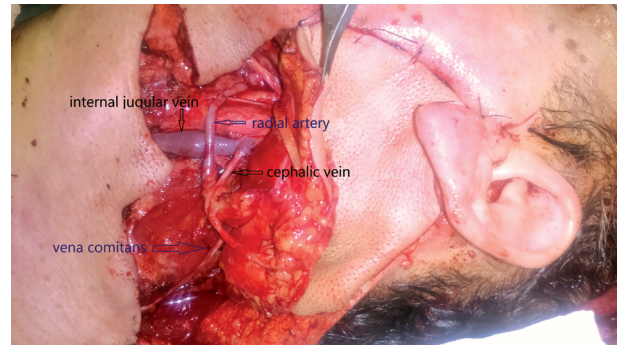


Fig. (2): Insetting and anastomosis of free radial forearm flap.

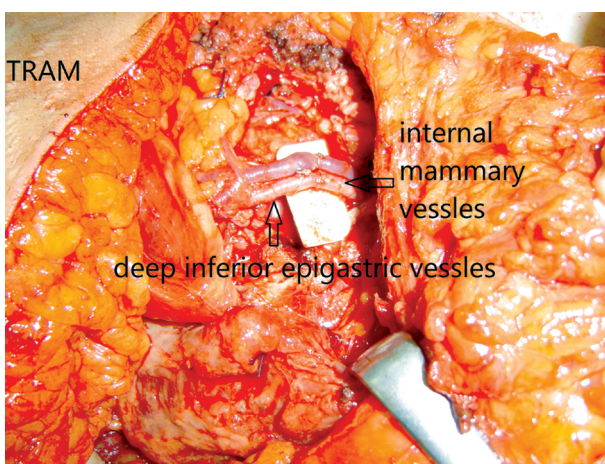


Fig. (3): Insetting and anastomosis of free TRAM flap.

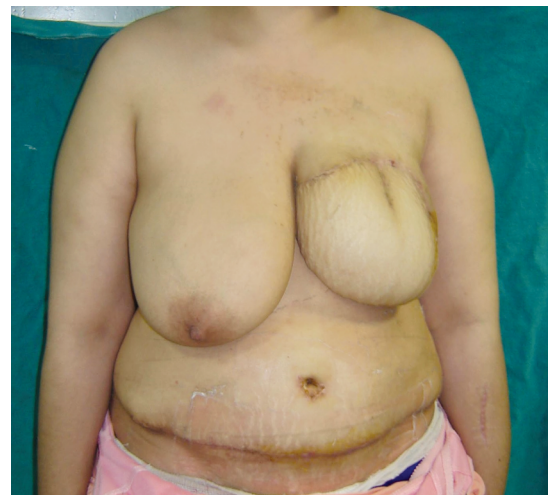

Fig. (4): Post operative photo of free TRAM flap.

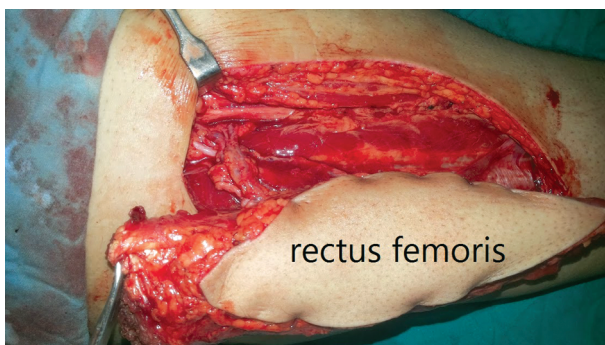


Fig. (5): Harvesting of free rectus femoris flap.

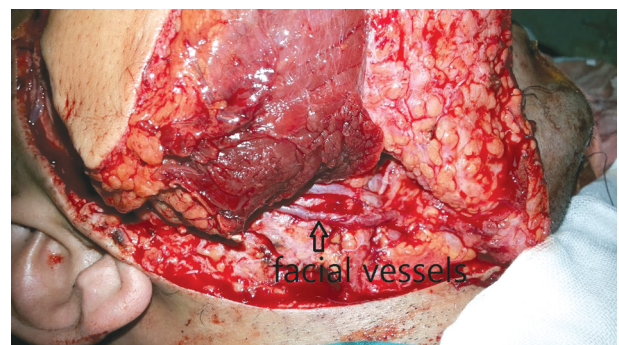


Fig. (6): Insetting and anastomosis of free rectus femoris.

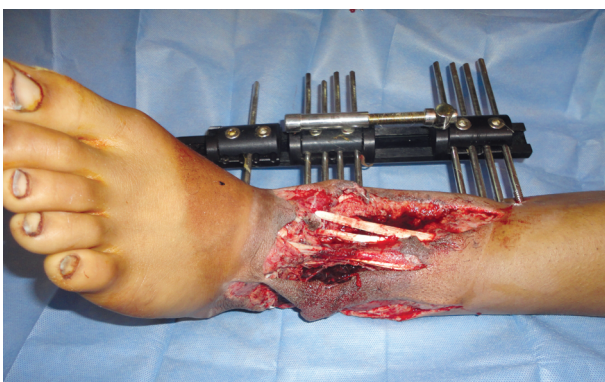

Fig. (7): Crushed lower third of leg.

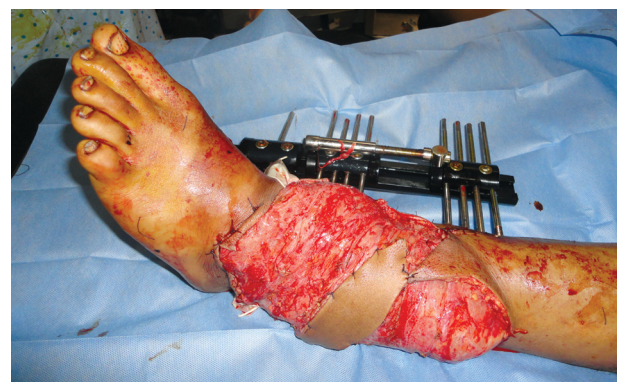

Fig. (8): Free latissimus dorsi.



## DISCUSSION

One of controversial points in microsurgery is the usefulness of dual venous anastomosis for free flap success [2]. While many surgeons advocate to do more than one venous anastomosis in each flap to raise their success rate [15-18] others deny this supposition [19,20] and hypothesized that, second anastomosis could increase the exposure of an endothelial defect, as well as it increases the probability for vessel twisting with increasing incidence for thrombosis [21].

After reviewing a long lasting studies of head and neck reconstruction after tumor resection and block neck dissection Ross and others have advocated to do double venous anastomosis to different venous systems (internal jugular and subclavian veins) if it is possible. They have marked a better success rate in flaps in which two vein were anastomosed (98.6% versus 93.6%). A considerable incidence of venous thrombosis after malignancy extirpation and block dissection [22] was another pretext to do double venous anastomosis to ensure good venous flow if thrombosis developed in one system [23,24]. The previous recommendation is supported by other recent works [21,25]. Ichinose and others studied the effect of dual venous anastomosis in free radial forearm flap, it has been found that a double venous anastomosis has no advantage over a single one if the anastomotic veins were attributed to the same venous system in the flaps (superficial or deep), but if one anastomosis was done in the superficial system (cephalic) and the other one in deep system (one of venae comitantes) the incidence of unwanted veins events were significantly reduced and the success rate was higher [2].

In his objective study, Hanasono and others measure blood flow through the flaps' veins when the flaps still in-situ (after complete dissection) and after flap transfer to the recipient area across the anastomotic sites, they have found that when one vena comitans was clamped before flap transfer or ligated after first venous anastomosis, there was a significant compensatory increase in flow velocity in patent vein [14]. This high flow status which resulted from single venous anastomosis could be beneficial in many ways, first it keeps the blood flow above thrombogenic threshold speed and improve intrinsic transit time in flap, [1,26,27] second it could confront the high venous pressure especially in lower limbs veins which is thought to be a one of causative factors for flap failure in this area [28]. And lastly single anastomosis reduce the operative time and consequently operative cost and morbidity [14].

After reviewing our work through last eight years and analyzing the results, we could not find a significant advantage for dual venous anastomosis over a single one in free flap transfer. The other unexpected find in our work was that, smoking had no significant difference in a complication rate nor flap success. Bianchi et al., reported a marked Major complications occurred in 24.7% of the flaps performed in smokers versus 17.3% of the flaps transferred in patients with no history of smoking [29], while Ichinose and his colleague have found that neither smoking nor hypertension had risk for flaps [2].

The majority of flap failure was in our earlier years in this study with subsequent improvement in success and reduction in operative time and reduction of postoperative complications, so although it is axiomatic, we emphasize on the effect of experience as a determinant factor for free flap success [30]. Holom and his colleague in their study that lasted for nine years noticed considerable reduction in both operative time and failure rate by the lapse of years. The same previous finding was mentioned by Klosterman and others after the analysis of their twenty years lasting study [31].

*Conclusion:* The second venous anastomosis does not have a significant role in free flap success.

## REFERENCES

- 1- Holm C., Dornseifer U., Sturtz G., Basso G., Schuster T. and Ninkovic M.: The intrinsic transit time of free microvascular flaps: Clinical and prognostic implications. *Microsurgery*, 30: 91-96, 2010.
- 2- Ichinose A., Terashi H., Nakahara M., Sugimoto I., Hashikawa K., Nomura T., et al.: Do multiple venous anastomoses reduce risk of thrombosis in free-flap transfer? Efficacy of dual anastomoses of separate venous systems. *Ann. Plast Surg.*, 52 (1): 61-3, 2004.
- 3- Pohlenz P., Blessmann M., Heiland M., Blake F., Schmelzle R. and Li L.: Postoperative complications in 202 cases of microvascular head and neck reconstruction. *J. Craniomaxillofac. Surg.*, 35: 311-315, 2007.
- 4- Fukuiwa T., Nishimoto K., Hayashi T. and Kurono Y.: Venous thrombosis after microvascular free-tissue transfer in head and neck cancer reconstruction. *Auris Nasus Larynx*, 35: 390-396, 2008.
- 5- Lucas G.L.: The pattern of venous drainage of the digits. *J. Hand Surg. (Am.)*, 9 (3): 448-50, 1984.
- 6- Matsuda M., Chikamatsu E. and Shimizu Y.: Correlation between number of anastomosed vessels and survival rate in finger replantation. *J. Reconstr. Microsurg.*, 9: 1-4, 1993.
- 7- Lee B.I., Chung H.Y., Kim W.K., Kim S.W. and Dhong E.S.: The effects of the number and ratio of repaired arteries and veins on the survival rate in digital replantation. *Ann. Plast. Surg.*, 44: 288-94, 2000.



- 8- Kroll S.S., Schusterman M.A., Reece G-P., et al.: Timing of pedicle thrombosis and flap loss after free-tissue transfer. *Plast. Reconstr. Surg.*, 48: 601-20, 1995.
- 9- Percival N.J., Sykes P.J. and Earley M.J.: Free flap surgery: The Welsh Regional Unit experience. *Br. J. Plast. Surg.*, 42: 435-40, 1989.
- 10- Alan Turner M.J.<sup>1</sup> and Smith W.P.: Double venous anastomosis for the radial artery forearm flap. Improving success and minimizing morbidity. *Journal of Cranio-Maxillofacial Surgery*, 37: 253-7, 2009.
- 11- Yang G.F., Chen P.J., Gao Y.Z., Liu X.Y., Li J., Jiang S.X. and He S.P.: Forearm free skin flap transplantation: A report of 56 cases: 1981. *Br. J. Plast. Surg.*, 50: 162-5, 1997.
- 12- Valentino J., Funk G.F., Hoffman H.T. and McCulloch T.J.: The communicating vein and its use in the radial forearm free flap. *Laryngoscope*, 106: 648-51, 1996.
- 13- Futran N.D. and Stack Jr. B.C.: Single versus dual venous drainage of the radial forearm free flap. *Am. J. Otolaryngol.*, 17 (2): 112-7, 1996.
- 14- Hanasono M.M., Kocak E., Ogunleye O., Hartley C.J. and Miller M.J.: One versus two venous anastomoses in microvascular free flap surgery. *Plast. Reconstr. Surg.*, 126 (5): 1548-57, 2010.
- 15- Yang G.F., Chen P.J., Gao Y.Z., Liu X.Y., Li J., Jiang S.X. and He S.P.: Forearm free skin flap transplantation: A report of 56 cases: 1981. *Br. J. Plast. Surg.*, 50: 162-5, 1997.
- 16- Harashina T.: Analysis of 200 free flaps. *Br. J. Plast. Surg.*, 41: 33-6, 1988.
- 17- Thoma A., Archibald S., Jackson S. and Young J.: Surgical patterns of venous drainage of the free forearm flap in head and neck reconstruction. *Plast. Reconstr. Surg.*, 93: 54-9, 1994.
- 18- Valentino J., Funk G.F., Hoffman H.T. and McCulloch T.J.: The communicating vein and its use in the radial forearm free flap. *Laryngoscope*, 106: 648-51, 1996.
- 19- Demirkan F., Wei F.C., Lutz B.S., Cher T.S. and Chen I.H.: Reliability of the venae comitantes in venous drainage of the free radial forearm flaps. *Plast. Reconstr. Surg.*, 102: 1544-8, 1998.
- 20- Futran N.D. and Stack B.C. Jr.: Single versus dual venous drainage of the radial forearm free flap. *Am. J. Otolaryngol.*, 17: 112-7, 1996.
- 21- Silverman D.A., Przylecki W.H., Arganbright J.M., Shnyder Y., Kakarala K. and Nazir N.: Revisiting the argument for 1-versus 2-vein outflow in head and neck free tissue transfers: A review of 317 microvascular reconstructions. *Head Neck*, 1-4 doi: 10.1002/hed.23976, 2015.
- 22- Brown D.H., Mulholland S., Yoo J.H., Gullane P.J., Irish J.C., Neligan P., et al.: Internal jugular vein thrombosis following modified neck dissection: Implications for head and neck flap reconstruction. *Head Neck*, 20: 169-174, 1998.
- 23- Ross G.L., Ang E.S., Golger A., Lannon D., Addison P., Snell L., et al.: Which venous system to choose for anastomosis in head and neck reconstructions? *Ann. Plast. Surg.*, 61 (4): 396-8, 2008.
- 24- Ross G.L., Ang E.S., Lannon D., Addison P., Golger A., Novak C.B., et al.: Ten-year experience of free flaps in head and neck surgery: How necessary is a second venous anastomosis? *Head Neck*, 30: 1086-1089, 2008.
- 25- Andrews B.T., Przylecki W.H., Silverman D.A., Arganbright J.M., Shnyder Y., Kakarala K., et al.: Does One or Two Vein Outflow Effect Outcomes in Head & Neck Microsurgery? Revisiting an Old Argument by Analyzing 317 Consecutive Free Tissue Transfers. *Plast. Reconstr. Surg.*, 134 (4S-1 Suppl): 11-12, 2014.
- 26- Esclamado R.M. and Carroll W.R.: The pathogenesis of vascular thrombosis and its impact in microvascular surgery. *Head Neck*, 21: 355-62, 1999.
- 27- Paloma V., Lasso J.M., Bazan A. and Serra J.M.: Relationship between flow and incidence of thrombosis in polytetrafluoroethylene vascular grafts in free microvascular flaps in lambs. *Scand J. Plast. Reconstr. Surg. Hand Surg.*, 33: 287-94, 1999.
- 28- Sakurai H., Yamaki T., Takeuchi M., Soejima K., Kono T. and Nozaki M.: Hemodynamic alterations in the transferred tissue to lower extremities. *Microsurgery*, 29: 101-106, 2009.
- 29- Bianchi B., Copelli C., Ferrari S., Ferri A. and Sesenna E.: Free flaps: Outcomes and complications in head and neck reconstructions. *J. Craniomaxillofac. Surg.*, 37 (8): 438-42, 2009.
- 30- Holom G.H., Seland H., Strandenes E., Liavaag P.G., Lybak S., Loes S., Tornes K. and Vintertun H.N.: Head and neck reconstruction using microsurgery: A 9-year retrospective study. *Eur. Arch. Otorhinolaryngol.*, 270 (10): 2737-43, 2013.
- 31- Klosterman T., Siu E. and Tatum S.: Free Flap Reconstruction Experience and Outcomes at a Low-Volume Institution over 20 Years. *Otolaryngology-Head and Neck Surgery*, 152 (5): 832-7, 2015.